

CLINICAL SCIENCE

Renal oxygen content is increased in healthy subjects after angiotensin-converting enzyme inhibition

Anna Stein,^{I,II} Silvia Goldmeier,^I Sarah Voltolini,^I Enio Setogutti,^{III} Carlos Feldman,^{I,III} Eduardo Figueiredo,^{IV} Renato Eick,^I Maria Irigoyen,^{I,VI} Katya Rigatto^V

^IFundação Universitária de Cardiologia (IC/FUC), Instituto de Cardiologia do Rio Grande do Sul, Porto Alegre/RS, Brazil. ^{II}Universidade Federal de São Paulo (UNIFESP), São Paulo, SP/Brazil. ^{III}Serviço de Investigação Diagnóstica (SIDI), Porto Alegre, RS/Brazil. ^{IV}MR Res Latin America GE Healthcare, São Paulo, SP/Brazil. ^VUniversidade Federal de Ciências da Saúde de Porto Alegre (UFCSPA), Departamento de Ciências Básicas da Saúde, Porto Alegre, RS/Brazil. ^{VI}Hospital das Clínicas da Faculdade de Medicina da Universidade de São Paulo, Instituto do Coração (InCor - USP), São Paulo, SP/Brazil.

OBJECTIVE: The association between renal hypoxia and the development of renal injury is well established. However, no adequate method currently exists to non-invasively measure functional changes in renal oxygenation in normal and injured patients.

METHOD: R2* quantification was performed using renal blood oxygen level-dependent properties. Five healthy normotensive women (50 ± 5.3 years) underwent magnetic resonance imaging in a 1.5T Signa Excite HDx scanner (GE Healthcare, Waukesha, WI). A multiple fast gradient-echo sequence was used to acquire R2*/T2* images (sixteen echoes from 2.1 ms/slice to 49.6 ms/slice in a single breath hold per location). The images were post-processed to generate R2* maps for quantification. Data were recorded before and at 30 minutes after the oral administration of an angiotensin II-converting enzyme inhibitor (captopril, 25 mg). The results were compared using an ANOVA for repeated measurements (mean ± standard deviation) followed by the Tukey test. ClinicalTrials.gov: NCT01545479.

RESULTS: A significant difference ($p < 0.001$) in renal oxygenation (R2*) was observed in the cortex and medulla before and after captopril administration: right kidney, cortex = 11.08 ± 0.56ms, medulla = 17.21 ± 1.47ms and cortex = 10.30 ± 0.44ms, medulla = 16.06 ± 1.74ms, respectively; and left kidney, cortex = 11.79 ± 1.85ms, medulla = 17.03 ± 0.88ms and cortex = 10.89 ± 0.91ms, medulla = 16.43 ± 1.49ms, respectively.

CONCLUSIONS: This result suggests that the technique efficiently measured alterations in renal blood oxygenation after angiotensin II-converting enzyme inhibition and that it may provide a new strategy for identifying the early stages of renal disease and perhaps new therapeutic targets.

KEYWORDS: BOLD; Renal Oxygenation; Healthy Subjects; Captopril; Renin-Angiotensin System.

Stein A, Goldmeier S, Voltolini S, Setogutti E, Feldman C, Figueiredo E, et al. Renal oxygen content is increased in healthy subjects after angiotensin-converting enzyme inhibition. *Clinics*. 2012;67(7):761-765.

Received for publication on February 27, 2012; First review completed on March 20, 2012; Accepted for publication on March 20, 2012

E-mail: steinanna87@gmail.com

Tel.: 55 51 3230-3757

INTRODUCTION

Despite advances in renal dialysis, there has been no substantial change in the mortality rate of acute renal failure over the past three decades. In contrast, over the same period, acute myocardial infarction mortality has fallen dramatically, from approximately 50% to 6% (1). In patients with end-stage renal disease, the mortality rate is growing because of the greater prevalence of hypertension and diabetes and the increased mean age of the population (2). Indeed, in the United States and Australia, approximately 11% of adults have some degree of chronic kidney disease

(3). In addition, the strong association between chronic kidney disease and cardiovascular disease has led the National Kidney Foundation and the American Heart Association to recommend that all patients with cardiovascular disease also be screened for kidney disease (4).

In cardiovascular disease, it is possible to precisely measure blood pressure, cholesterol or glucose concentration. However, it is still very difficult to identify early-stage renal injury, and current laboratory measurements are insufficient for making an early diagnosis. In addition, traditional imaging methods, although excellent for morphologic assessments, are limited in detecting premature renal functional alterations (5). The sequence of events that reduces renal oxygenation leading to ischemia and/or kidney injury is still unknown (6). Glomerular hyperfiltration (7) or tubulointerstitial damage (8) can cause progressive and irreversible renal failure, regardless of the initial insult. In fact, histological studies in human kidneys showed that tubulointerstitial oxygenation is modified before structural

Copyright © 2012 CLINICS – This is an Open Access article distributed under the terms of the Creative Commons Attribution Non-Commercial License (<http://creativecommons.org/licenses/by-nc/3.0/>) which permits unrestricted non-commercial use, distribution, and reproduction in any medium, provided the original work is properly cited.

No potential conflict of interest was reported.

microvascular damage takes place. This observation indicates that morphological changes begin in a very early stage of kidney disease (9). At this stage, it is not possible to diagnose renal pathology using the methods available. Thus, a method for detecting the early stages of renal functional changes would be very useful for the early treatment of renal disease. Unfortunately, renal biopsy is the only current method of confirm functional alteration (5).

From the late 1980s, when Brezis (1991) (10) inserted microelectrodes into the Sprague-Dawley rats renal parenchyma to demonstrate hypoxic changes during acute kidney injury, to the 1990s, when Prasad introduced blood oxygen level-dependent (BOLD) magnetic resonance imaging (MRI) to the study of renal blood flow (11), several different factors have been blamed for the slow progress of the prevention and treatment of acute or chronic renal failure.

There is no doubt that the renin angiotensin system (RAS) is useful to preserve peritubular capillary perfusion under normal situations (12). However, when it is excessively stimulated, the RAS can induce renal hypoxia, reducing the efficiency of oxygen diffusion in renal tissue and provoking functional (13) and structural changes, damage to the renal vasculature and fibrosis (14).

In the present study, we measured the intra-renal effect of ACE inhibition on healthy subjects using a sensitive BOLD-MRI method that uses deoxygenated hemoglobin as an endogenous contrast agent. The ratio of oxyhemoglobin (diamagnetic) to deoxyhemoglobin (paramagnetic) is proportional to the partial oxygen pressure (pO_2). The BOLD signal is estimated using the transverse relaxation rate $R2^*$ ($1/T2^*$) and can be considered a sensitive indicator of tissue pO_2 . However, an inverse ratio also exists; when this signal is increased, renal oxygenation is decreased, and vice versa (11,15).

Therefore, considering that angiotensin II (Ang II) reduces renal blood flow, (16-17) we hypothesized that partial ACE inhibition would increase the BOLD-MRI signal in renal tissue. The study of the mechanism underlying this putative process and the responses to ACE inhibition is of considerable importance. Understanding the mechanisms by which the kidney adapts to the effects of the RAS in healthy subjects will be useful for the early detection of renal disease and for the development of new therapies to decrease the progression of the disease and its consequences.

METHODS

Subjects

The study was conducted under protocol (n° 4111/08), approved by the Ethics Committee of the *Instituto de Cardiologia do Rio Grande do Sul-Fundação Universitária de Cardiologia/Brazil*. After providing informed consent, five healthy female volunteers (50 ± 5.3 years old) participated in the study. None of the subjects were taking any medications, and they were asked to abstain from food and water overnight. All measurements were performed in the late morning.

After a baseline BOLD-MRI acquisition, the subjects were given an oral ACE inhibitor (captopril 25 mg). Thirty minutes after captopril administration, without moving from the scanner, blood pressure was measured and a second BOLD acquisition was performed to detect possible changes in renal oxygenation. Data were collected by two radiologists and interpreted by a physician and a physiologist.

MR Imaging Technique

Images were acquired using a 1.5T HDx instrument (Sigma, GE Healthcare, Waukesha, WI) and an 8-channel body coil.

Localizer images were performed in the axial and sagittal planes following the long axis of both kidneys, using the fast spoiled gradient echo (FSPGR) technique while the patients held their breath.

Oblique axial and coronal reference images were acquired to construct color maps following approximately the short and long axes of both kidneys using FSPGR with the following parameters: field of view (FOV) = 40 cm, matrix 256×128 , slice thickness = 5 cm, slice gap 6 cm, 3 slices per plane in one breath hold, repetition time (RT) = 150 ms, echo time (ET) = min full, angle degrees (FLIP) = 90, band width (rBW) = 62KHz, 1NEX. This sequence provides an excellent contrast between the cortex and the medulla and avoids the unnecessary use of contrast agents.

BOLD-sensitive images were acquired using the multiple echo FGRE sequence with the same geometrical parameters. The reference images considered the following parameters: TR = 60 ms, FLIP = 30, rBW = 60 KHz, 16 echoes from TE = 2.1 ms until 49.6 ms, an echo interval of 3.2 ms, 1 NEX.

BOLD imaging Data Processing

Bold image processing was performed using the Functool $R2^*$ module for $R2^*/T2^*$ fitting, assuming single exponential decay without constant offset at AW4.3 (GE Healthcare).

For visualization and quantification, $R2^*$ parametric maps were generated for each slice (11,18-19). A Puh-Thallium color table was used because the data had a dynamic range with a minimum value set at 7.0/sec and a maximum value at 23/sec. The color ranged from blue to red from the minimum $R2^*$ to the maximum $R2^*$, respectively. Green/yellow coloring represents intermediate $R2^*$. When a position mismatch occurred due to a different breath hold state, anatomical fat-suppressed FSPGR images were used as transparent references over a parametric map or the original BOLD images.

Three slices were acquired, and the slice that provided the best differentiation between the cortex and the medulla and the minimum partial volume was selected for quantification. A total of six regions of interest (ROIs) with a pixel size of nine were used for each plane; three regions were positioned at the cortex and three were positioned at the medulla.

The ROIs were positioned at the cortex according to the anatomical reference image (light gray) and blue on the parametric map. The ROIs were positioned at the medulla using either the anatomical reference image (dark gray) or the parametric map that showed a green, yellow and red gradient (Figure 1). Areas with susceptibility artifacts, such as bowel gas, and areas with renal hilum vessels were avoided.

Data analysis

The statistical significance was determined using an analysis of variance for three repeated measures (ANOVA) followed by the Tukey test (SPSS 12.0). The data are presented as the mean \pm SD. $P < 0.05$ was considered statistically significant.

RESULTS

Table 1 summarizes the $R2^*$ measurements of the left and right kidney in the cortex and medulla before and after ACE

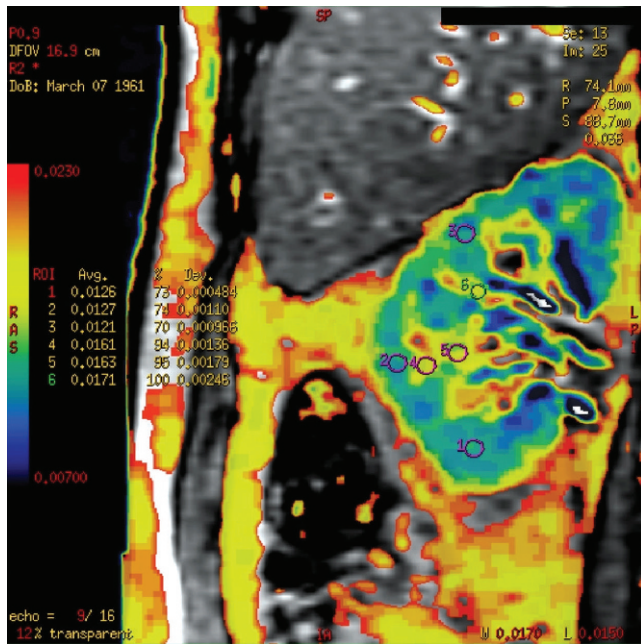


Figure 1 - An R2* map superimposed on the anatomic image of the 9th echo. The lowest R2* was set to 7 Hz (blue), and the maximum R2* was set to 23 Hz (red). The intermediate values range from green and yellow to orange according to the color scale on the left.

inhibitor administration. Our results consistently indicate that moderate ACE inhibition reduced the R2* BOLD-MRI signal in the cortex and medulla and, therefore, increased renal blood flow. For all subjects, the R2* values were significantly higher in the medulla than in the cortex, and there was a significant difference between the baseline values and those obtained thirty minutes after ACE inhibitor administration (Table 1). No significant differences were observed for the values within subjects or between subjects for the cortex and medulla in the three measurements (data not shown).

The volunteers had an initial medial systolic blood pressure of 113 ± 12 mmHg and a diastolic pressure of 76 ± 5 mmHg. Thirty minutes after captopril administration, systolic but not diastolic blood pressure showed a modest but significant decrease. However, the systolic blood pressure did not significantly differ between 30 and 60 minutes after captopril administration (Table 2).

Hematocrit (37 ± 3.6%) and hemoglobin (12 ± 1.2 mEq/L) and the plasma concentrations of sodium (139 ± 3.9 mEq/L), potassium (3.8 ± 0.6 mEq/L) and creatinine (0.6 ± 0.1 mEq/L) (n=4) were measured in the clinical laboratory of the Instituto de Cardiologia do Rio Grande do Sul.

Table 1 - R2* signal (ms) in the renal cortex and medulla in five healthy kidneys before (control) and at 30 minutes after the oral administration of an ACE inhibitor.

	Cortex		Medulla	
	Control	After captopril	Control	After captopril
Right kidney	11.08 ± 0.56	10.30 ± 0.44 [†]	17.21 ± 1.47 [*]	16.06 ± 1.74 ^{*†}
Left kidney	11.79 ± 1.85	10.89 ± 0.91 [†]	17.03 ± 0.88 [*]	16.43 ± 1.49 ^{*†}

*p < 0.001 vs. cortex (control and captopril), †p < 0.001 vs. control (medulla and cortex), ACE = angiotensin-converting enzyme.

DISCUSSION

The main finding of this study is that the oral administration of a low dose of an ACE inhibitor allowed the early detection of an increase in renal cortical and medullary oxygenation using BOLD-MRI. This result is consistent with the very well-established property of Ang II to decrease renal perfusion and renal oxygenation (16-17). Ang II is known to be responsible for the majority of the physiological and pathological effects of RAS, and ACE inhibition reduces Ang II formation. Ang II inhibition has been highly successful in hypertension management and for reducing renal disease progression (20-21).

Renal hypoxia has long been considered important in the development of renal disease due to diabetes mellitus (22). Ries et al. used the BOLD-MRI technique in an animal model and observed a significant decrease in oxygenation in the kidneys of diabetic patients compared to controls (23). Several studies on the pathogenesis of essential hypertension have also shown that medullary blood flow reduction is one of the most important factors in the development of the renal disease (24). However, a chronic infusion of a suppressor Ang II dose induces a long-term increase in BP. This effect could be associated with the afferent arteriolar reactivity to Ang II and might be present in the early stages of hypertension (25). These findings and the fact that Ang II decreases renal oxygenation support the utility of BOLD-MRI for the study of the pathophysiology of hypertension (26-27).

Thus, efforts to measure functional renal oxygenation with the use of captopril, a renin Ang II axis inhibitor, provide data that is relevant to the prevention and treatment of renal diseases (26-27).

ACE inhibition and the subsequent reduction in Ang II plasma concentration (28) most likely provoked renal arteriolar vasodilatation and increased renal blood flow and oxygenation. Thus, the decrease in R2* signal observed in the cortex and medulla likely occurred due to the increase in tissue pO2 (11,15) induced by moderate ACE inhibition. These findings support the idea that kidney oxygen content depends on both tubular sodium reabsorption and renal blood flow (29) and reinforce the idea that R2* has an inverse correlation with oxygen content and blood flow (11,30).

The results obtained using renal BOLD-MRI in the presence of Ang II are most likely a consequence of reduced perfusion rather than of increased renal oxygen consumption (31). Thus, the mechanism for improving oxygenation by Ang II blockade includes both hemodynamic changes and efficient oxygen usage (14). These findings are consistent with our results, which indicated that the effects of the RAS were not exclusively associated with BP, although they were principally associated with renal perfusion.

Table 2 - Blood pressure measurements before and at 15, 30 and 60 minutes after the oral administration of an ACE inhibitor (n = 5).

Time (minutes)	Before ACEi		15		30		60	
	Systolic	Diastolic	Systolic	Diastolic	Systolic	Diastolic	Systolic	Diastolic
BP (mmHg)	113 ± 12	76 ± 5	108 ± 13	70 ± 6	105 ± 8*	69 ± 3	103 ± 12**	69 ± 5

ACEi = angiotensin-converting enzyme inhibition; BP = Blood Pressure;
*p < 0.05 and **p < 0.01 vs. systolic BP before ACEi

The right and left kidneys did not have significantly different R2* values. It should also be emphasized that our control R2* values are very close to those found in the literature (11,15,32-35) for baseline measurements.

We recorded the BOLD signal after thirty minutes instead of 60 minutes because 25 mg of captopril decreased the systolic blood pressure (BP) equally at both time points. Thus, our protocol predicted the second BOLD signal acquisition after 30 minutes to avoid maintaining the subjects in a static position inside the scanner for an unnecessarily long period of time.

We believe that the decrease in systolic blood pressure observed in the first 30 minutes did not interfere with renal oxygenation. In support of this assumption, Schachinger recently demonstrated that vasoactive substances, such as noradrenalin and sodium nitroprusside, did not alter the renal BOLD signal, although they were able to provoke BP changes (31). Ang II infusion is also known to decrease the renal BOLD signal as quickly as 10 s after the peripheral intravenous administration of an Ang II bolus. This is clearly faster than the arterial blood pressure response, suggesting that it may be related to reduced renal perfusion rather than to metabolic adjustment (31).

Several studies have also demonstrated that, at lower concentrations, Ang II may cause greater vasoconstriction in the medulla than in the cortex. The authors hypothesize that this effect is likely related to the greater Ang II receptor density in the outer medulla (36-37). In fact, we also found that, under normal conditions, the oxygen content was significantly higher in the cortex than in the medulla. This result was maintained after ACE inhibition, indicating that the physiological balance between cortical and medullary circulation did not change after a moderate reduction of the Ang II in the blood stream.

Our results are consistent with those of many investigators who showed that BOLD detected a higher oxygen content in the cortex than in the medulla (11,19,34,38).

Thus, BOLD-MRI is a useful, non-invasive tool for defining basic physiological mechanisms, and it will contribute to a better understanding of regional oxygenation within the kidney (39).

BOLD-MRI has opened an exciting new area for studying renal physiopathology and has created new possibilities for identifying the early stages of renal disease and perhaps new therapeutic targets (40).

However, this study has several important limitations: 1- we did not include a placebo group; 2- the subject number was small; and 3- the study was conducted only in females. It is also important to note that subjects were not removed from the scanner prior to the second BOLD acquisition. Moreover, the conditions were the same during the data

collection for all subjects, indicating that renal oxygenation was increased after captopril administration.

There is considerable interest in developing techniques that will enable physicians to identify and evaluate early changes in tissue function. BOLD-MRI may be a very useful technique for the early assessment of renal injuries in clinical practice. More studies should be conducted to confirm this hypothesis.

ACKNOWLEDGMENTS

We wish to thank the volunteers for their contribution to science and Sergio Kakuta Kato and Angelo de Souza for their assistance.

AUTHOR CONTRIBUTIONS

Stein A recorded data, participated in the analysis and interpretation of data, statistical analysis, and manuscript writing. Goldmeier S, Voltolini S, Setogutti E, Feldman C, and Figueiredo E recorded and interpreted data. Eick R analyzed and interpreted data and participated in manuscript writing. Rigatto K interpreted data and drafted and critically revised the manuscript. Irigoyen MC participated in the conception and design of the study, analyzed and interpreted data and drafted and critically revised the manuscript. All authors read and approved the final manuscript.

REFERENCES

1. Mehta RL, Chertow GM. Acute renal failure definitions and classification: time for change? *J Am Soc Nephrol.* 2003;14(8):2178-87, <http://dx.doi.org/10.1097/01.ASN.0000079042.13465.1A>.
2. Alcazar JM, Rodicio JL. Ischemic nephropathy: clinical characteristics and treatment. *Am J Kidney Dis.* 2000;36(5):883-93, <http://dx.doi.org/10.1053/ajkd.2000.19077>.
3. Bello AK, Nwankwo E, El Nahas AM. Prevention of chronic kidney disease: a global challenge. *Kidney Int Suppl.* 2005(98):S11-7.
4. Brosius FC 3rd, Hostetter TH, Kelepouris E, Mitsnefes MM, Moe SM, Moore MA, et al. Detection of chronic kidney disease in patients with or at increased risk of cardiovascular disease: a science advisory from the American Heart Association Kidney and Cardiovascular Disease Council; the Councils on High Blood Pressure Research, Cardiovascular Disease in the Young, and Epidemiology and Prevention; and the Quality of Care and Outcomes Research Interdisciplinary Working Group: Developed in Collaboration With the National Kidney Foundation. *Hypertension.* 2006;48(4):751-5.
5. Wang TM, Chang PL, Kao PF, Hsieh ML, Huang ST, Tsui KH. The role of diuretic renography in the evaluation of obstructed hydronephrosis after pediatric pyeloplasty. *Chang Gung Med J.* 2004;27(5):344-50.
6. Textor SC, Glockner JF, Lerman LO, Misra S, McKusick MA, Riederer SJ, et al. The use of magnetic resonance to evaluate tissue oxygenation in renal artery stenosis. *J Am Soc Nephrol.* 2008;19(4):780-8, <http://dx.doi.org/10.1681/ASN.2007040420>.
7. Brenner BM, Goldsizer RC, Hostetter TH. Glomerular response to renal injury. *Contrib Nephrol.* 1982;33:48-66.
8. Nangaku M. Mechanisms of tubulointerstitial injury in the kidney: final common pathways to end-stage renal failure. *Intern Med.* 2004;43(1):9-17, <http://dx.doi.org/10.2169/internalmedicine.43.9>.
9. Nangaku M. Chronic hypoxia and tubulointerstitial injury: a final common pathway to end-stage renal failure. *J Am Soc Nephrol.* 2006;17(1):17-25.
10. Heyman SN, Brezis M, Epstein FH, Spokes K, Silva P, Rosen S. Early renal medullary hypoxic injury from radiocontrast and indomethacin. *Kidney Int.* 1991;40(4):632-42, <http://dx.doi.org/10.1038/ki.1991.255>.

11. Prasad PV, Edelman RR, Epstein FH. Noninvasive evaluation of intrarenal oxygenation with BOLD MRI. *Circulation*. 1996;94(12):3271-5.
12. Nangaku M, Inagi R, Miyata T, Fujita T. Angiotensin-induced hypoxia in the kidney: functional and structural changes of the renal circulation. *Adv Exp Med Biol*. 2007;618:85-99, http://dx.doi.org/10.1007/978-0-387-75434-5_7.
13. Kondo N, Kiyomoto H, Yamamoto T, Miyatake A, Sun GP, Rahman M, et al. Effects of calcium channel blockade on angiotensin II-induced peritubular ischemia in rats. *J Pharmacol Exp Ther*. 2006;316(3):1047-52.
14. Nangaku M, Fujita T. Activation of the renin-angiotensin system and chronic hypoxia of the kidney. *Hypertens Res*. 2008;31(2):175-84, <http://dx.doi.org/10.1291/hypres.31.175>.
15. Prasad PV, Chen Q, Goldfarb JW, Epstein FH, Edelman RR. Breath-hold R2* mapping with a multiple gradient-recalled echo sequence: application to the evaluation of intrarenal oxygenation. *J Magn Reson Imaging*. 1997;7(6):1163-5, <http://dx.doi.org/10.1002/jmri.1880070633>.
16. Schachinger H, Dieterle T, Martina B, Haberthur C, Huber PR, Bock A, et al. Increased renovascular response to angiotensin II in persons genetically predisposed to arterial hypertension disappears after chronic angiotensin-converting enzyme inhibition. *J Hypertens*. 2004;22(1):175-80, <http://dx.doi.org/10.1097/00004872-200401000-00027>.
17. Hall JE, Granger JP. Renal hemodynamic actions of angiotensin II: interaction with tubuloglomerular feedback. *Am J Physiol*. 1983;245(2):R166-73.
18. Sadowski EA, Fain SB, Alford SK, Korosec FR, Fine J, Muehrer R, et al. Assessment of acute renal transplant rejection with blood oxygen level-dependent MR imaging: initial experience. *Radiology*. 2005;236(3):911-9, <http://dx.doi.org/10.1148/radiol.2363041080>.
19. Epstein FH, Prasad P. Effects of furosemide on medullary oxygenation in younger and older subjects. *Kidney Int*. 2000;57(5):2080-3, <http://dx.doi.org/10.1046/j.1523-1755.2000.00057.x>.
20. Johnston CI. Tissue angiotensin converting enzyme in cardiac and vascular hypertrophy, repair, and remodeling. *Hypertension*. 1994;23(2):258-68.
21. Dzau VJ. Theodore Cooper Lecture: Tissue angiotensin and pathobiology of vascular disease: a unifying hypothesis. *Hypertension*. 2001;37(4):1047-52.
22. Prasad P, Li LP, Halter S, Cabray J, Ye M, Battle D. Evaluation of Renal Hypoxia in Diabetic Mice by BOLD MRI. *Investigative radiology*. 2010;45(12):819-22, <http://dx.doi.org/10.1097/RLI.0b013e3181ec9b02>.
23. Ries M, Basseau F, Tyndal B, Jones R, Deminiere C, Catargi B, et al. Renal diffusion and BOLD MRI in experimental diabetic nephropathy. Blood oxygen level-dependent. *J Magn Reson Imaging*. 2003;17(1):104-13, <http://dx.doi.org/10.1002/jmri.10224>.
24. Mattson DL, Roman RJ, Cowley AW Jr. Role of nitric oxide in renal papillary blood flow and sodium excretion. *Hypertension*. 1992;19(6 Pt 2):766-9.
25. Imig JD. Afferent arteriolar reactivity to angiotensin II is enhanced during the early phase of angiotensin II hypertension. *Am J Hypertens*. 2000;13(7):810-8, [http://dx.doi.org/10.1016/S0895-7061\(00\)00264-8](http://dx.doi.org/10.1016/S0895-7061(00)00264-8).
26. Solski LV, Longyore DS. Prevention of type 2 diabetes mellitus with angiotensin-converting-enzyme inhibitors. *Am J Health Syst Pharm*. 2008;65(10):935-40, <http://dx.doi.org/10.2146/ajhp070388>.
27. Chen SX, Song T, Zhou SH, Liu YH, Wu SJ, Liu LY. Protective effects of ACE inhibitors on vascular endothelial dysfunction induced by exogenous advanced oxidation protein products in rats. *European journal of pharmacology*. 2008;584(2-3):368-75, <http://dx.doi.org/10.1016/j.ejphar.2008.02.020>.
28. Badzyska B, Sadowski J. Opposed effects of prostaglandin E2 on perfusion of rat renal cortex and medulla: interactions with the renin-angiotensin system. *Experimental physiology*. 2008;93(12):1292-302, <http://dx.doi.org/10.1113/expphysiol.2008.043604>.
29. Kellerman PS. Cellular and metabolic consequences of chronic ischemia on kidney function. *Semin Nephrol*. 1996;16(1):33-42.
30. Juillard L, Lerman LO, Kruger DG, Haas JA, Rucker BC, Polzin JA, et al. Blood oxygen level-dependent measurement of acute intra-renal ischemia. *Kidney Int*. 2004;65(3):944-50, <http://dx.doi.org/10.1111/j.1523-1755.2004.00469.x>.
31. Schachinger H, Klarhofer M, Linder L, Drewe J, Scheffler K. Angiotensin II decreases the renal MRI blood oxygenation level-dependent signal. *Hypertension*. 2006;47(6):1062-6, <http://dx.doi.org/10.1161/01.HYP.000.0220109.98142.a3>.
32. Simon-Zoula SC, Hofmann L, Giger A, Vogt B, Vock P, Frey FJ, et al. Non-invasive monitoring of renal oxygenation using BOLD-MRI: a reproducibility study. *NMR Biomed*. 2006;19(1):84-9, <http://dx.doi.org/10.1002/nbm.1004>.
33. Hofmann L, Simon-Zoula S, Nowak A, Giger A, Vock P, Boesch C, et al. BOLD-MRI for the assessment of renal oxygenation in humans: acute effect of nephrotoxic xenobiotics. *Kidney Int*. 2006;70(1):144-50, <http://dx.doi.org/10.1038/sj.ki.5000418>.
34. Epstein FH, Veves A, Prasad PV. Effect of diabetes on renal medullary oxygenation during water diuresis. *Diabetes Care*. 2002;25(3):575-8, <http://dx.doi.org/10.2337/diacare.25.3.575>.
35. Zuo CS, Rofsky NM, Mahallati H, Yu J, Zhang M, Gilbert S, et al. Visualization and quantification of renal R2* changes during water diuresis. *J Magn Reson Imaging*. 2003;17(6):676-82, <http://dx.doi.org/10.1002/jmri.10314>.
36. Blantz RC, Konnen KS, Tucker BJ. Angiotensin II effects upon the glomerular microcirculation and ultrafiltration coefficient of the rat. *J Clin Invest*. 1976;57(2):419-34, <http://dx.doi.org/10.1172/JCI108293>.
37. Navar LG, Inscho EW, Majid SA, Imig JD, Harrison-Bernard LM, Mitchell KD. Paracrine regulation of the renal microcirculation. *Physiol Rev*. 1996;76(2):425-536.
38. Prasad PV, Epstein FH. Changes in renal medullary pO2 during water diuresis as evaluated by blood oxygenation level-dependent magnetic resonance imaging: effects of aging and cyclooxygenase inhibition. *Kidney Int*. 1999;55(1):294-8, <http://dx.doi.org/10.1046/j.1523-1755.1999.00237.x>.
39. Głowiczki ML, Lerman LO, Textor SC. Blood Oxygen Level-Dependent (BOLD) MRI in Renovascular Hypertension. *Current hypertension reports*. 13(5):370-7.
40. Chrysochou C, Mendichovszky IA, Buckley DL, Cheung CM, Jackson A, Kalra PA. BOLD imaging: a potential predictive biomarker of renal functional outcome following revascularization in atheromatous renovascular disease. *Nephrol Dial Transplant*. 2012;27(3):1013-9, <http://dx.doi.org/10.1093/ndt/gfr392>.