

See discussions, stats, and author profiles for this publication at: <https://www.researchgate.net/publication/319447059>

B-lines with Lung Ultrasound: The Optimal Scan Technique at Rest and During Stress

Article in *Ultrasound in Medicine & Biology* · September 2017

DOI: 10.1016/j.ultrasmedbio.2017.07.007

CITATION

1

READS

32

48 authors, including:



Eugenio Picano

Italian National Research Council

677 PUBLICATIONS 17,770 CITATIONS

[SEE PROFILE](#)



Giovanni Di salvo

Royal Brompton and Harefield NHS Foundati...

275 PUBLICATIONS 4,967 CITATIONS

[SEE PROFILE](#)



Dario Gregori

University of Padova

429 PUBLICATIONS 5,299 CITATIONS

[SEE PROFILE](#)

Some of the authors of this publication are also working on these related projects:



Stress Echocardiography 2020 [View project](#)



Implementing 3D echocardiography in the clinical practice of the echocardiographic laboratory [View project](#)

All content following this page was uploaded by [Marcelo Haertel Miglioranza](#) on 03 September 2017.

The user has requested enhancement of the downloaded file.



<http://dx.doi.org/10.1016/j.ultrasmedbio.2017.07.007>

● *Original Contribution*

B-LINES WITH LUNG ULTRASOUND: THE OPTIMAL SCAN TECHNIQUE AT REST AND DURING STRESS

MARIA CHIARA SCALI,^{*†} ANGELA ZAGATINA,[‡] IANA SIMOVA,[§] NADEZHDA ZHURAVSKAYA,[‡]
 QUIRINO CIAMPI,[¶] MARCO PATERNI,^{||} MARIO MARZILLI,[†] CLARA CARPEGGIANI,^{||} and EUGENIO PICANO^{||}
 ON BEHALF OF THE STRESS ECHO 2020 STUDY GROUP OF THE ITALIAN SOCIETY OF CARDIOVASCULAR
 ECHOGRAPHY (SIEC)

*Cardiology Division, Nottola Hospital, Siena, Italy; †Cardiothoracic Department, Cisanello, Pisa, Italy; ‡Cardiology Department, Medika Cardiocenter, Saint Petersburg, Russian Federation; §Acibadem City Clinic Cardiovascular Center, University Hospital, Sofia, Bulgaria; ¶Cardiology Division, Fatebenefratelli Hospital, Benevento, Italy; and ||CNR, Institute of Clinical Physiology, Biomedicine Department, Pisa, Italy

(Received 3 April 2017; revised 16 June 2017; in final form 10 July 2017)

Abstract—Various lung ultrasound (LUS) scanning modalities have been proposed for the detection of B-lines, also referred to as *ultrasound lung comets*, which are an important indication of extravascular lung water at rest and after exercise stress echo (ESE). The aim of our study was to assess the lung water spatial distribution (*comet map*) at rest and after ESE. We performed LUS at rest and immediately after semi-supine ESE in 135 patients (45 women, 90 men; age 62 ± 12 y, resting left ventricular ejection fraction = $41 \pm 13\%$) with known or suspected heart failure or coronary artery disease. B-lines were measured by scanning 28 intercostal spaces (ISs) on the antero-lateral chest, 2nd–5th IS, along with the midaxillary (MA), anterior axillary (AA), mid-clavicular (MC) and parasternal (PS) lines. Complete 28-region, 16-region (3rd and 4th IS), 8-region (3rd IS), 4-region (3rd IS, only AA and MA) and 1-region (left 3rd IS, MA) scans were analyzed. In each space, the B-lines were counted from 0 = black lung to 10 = white lung. Interpretable images were obtained in all spaces (feasibility = 100 %). B-lines (>0 in at least 1 space) were present at ESE in

Address correspondence to: Eugenio Picano, Institute of Clinical Physiology, National Research Council, Via Moruzzi, 1 - 56 124, Pisa, Italy. E-mail: picano@ifc.cnr.it

On behalf of the Stress Echo 2020 Study Group of the Italian Society of Cardiovascular Echography: Eugenio Picano,* Quirino Ciampi,† Rodolfo Citro,‡ Antonello D'Andrea,§ Maria Chiara Scali,¶ Lauro Cortigiani,|| Jacopo Olivetto,# Fabio Mori,## Maurizio Galderisi,** Marco Fabio Costantino,†† Lorenza Pratali,* Giovanni di Salvo,‡‡ Eduardo Bossone,‡ Francesco Ferrara,‡ Jaroslaw D. Kasprzak,§§ Fausto Rigo,¶¶ Nicola Gaibazzi,||| Giuseppe Limongelli,### Giuseppe Pacileo,*** Sergio Severino,*** Bruno Pinamonti,††† Laura Massa,††† Marco A. R. Torres,††† Marcelo H. Miglioranza,§§§ Clarissa Borguezan Daros,¶¶¶ José Luis de Castro e Silva Pretto,||||| Ana Djordjevic-Dikic,### Milica Dekleva,**** Albert Varga,†††† Gergely Agoston,†††† Attila Palinkas,†††† Angela Zagatina,§§§§ Iana Simova,¶¶¶¶ Miguel Amor,||||| Jorge Lowenstein,#### Pablo Merlo,#### Jelena Celutkicene,***** Julio E. Perez,††††† Paolo Trambaiolo,††††† Dario Gregori,§§§§§ Paolo Colonna,¶¶¶¶¶ Maria Grazia Andreassi,* Michele De Nes,* Ayana Arystan,* Marco Paterni* and Clara Carpeggiani*.

*Institute of Clinical Physiology, National Research Council, Pisa, Italy; †Cardiology Division, Fatebenefratelli Hospital, Benevento, Italy; ‡Heart Department, University Hospital “San Giovanni di Dio e Ruggi d’Aragona”, Salerno, Italy; §Division of Cardiology, Monaldi Hospital, Second University of Naples, Italy; ¶Cardiology Department, Pisa Cisanello University Hospital and Nottola (Siena) Hospital, Italy; ||Cardiology Department, San Luca Hospital, Lucca, Italy; #Cardiology Department, Careggi Hospital, Florence, Italy; **Department of Advanced Biomedical Sciences, Federico II University Hospital, Naples, Italy; ††Cardiology Department, San Carlo Hospital, Potenza, Italy;

‡‡Pediatric Cardiology Department, Brompton Hospital, London, UK; §§Division of Cardiology, Chair of Cardiology, Bieganski Hospital, Medical University, Lodz Poland; ¶¶Ospedale dell’Angelo Mestre-Venice, Italy; ||||Cardiology Department, Parma University Hospital, Italy; ###Pediatric Cardiology Department, Monaldi Hospital Clinics, Second University of Naples, Italy; ***Division of Cardiology, Monaldi Hospital Clinics, Second University of Naples, Italy; †††Cardiology Department, University Hospital “Ospedale Riuniti”, Trieste, Italy; ‡‡‡Hospital de Clinicas de Porto Alegre—Universidade Federal do Rio Grande do Sul, Porto Alegre, Brasil; §§§Cardiology Institute of Rio Grande do Sul, Porto Alegre, Brasil; ¶¶¶Cardiology Division, Hospital San José, Criciúma, Brasil; |||||Hospital Sao Vicente de Paulo e Hospital de Cidade, Passo Fundo, Brasil; ####Cardiology Clinic, Clinical Center of Serbia, Medical School, University of Belgrade, Belgrade; ****Clinical Hospital Zvezdara Belgrade, Serbia; ††††Institute of Family Medicine, University of Szeged, Hungary; †††††Department of Internal Medicine, Elisabeth Hospital, Hodmezovasarhely, Hungary; §§§§Cardiology Department, Medika Cardiocenter, Saint Petersburg, Russian Federation; ¶¶¶¶Acibadem City Clinic Cardiovascular Center, University Hospital, Sofia, Bulgaria; |||||Cardiology Department, Ramos Mejia Hospital, Buenos Aires, Argentina; ####Cardiodiagnosticos, Investigaciones Medicas, Buenos Aires, Argentina; *****Centre of Cardiology and Angiology, Vilnius University Hospital Santariškių Klinikos, Vilnius, Lithuania; †††††Washington University School of Medicine, Barnes-Jewish Hospital, St. Louis, MO, USA; †††††Department of Cardiology, Sandro Pertini Hospital, Rome, Italy; and §§§§§Department of Biostatistics, University of Padua, Italy; ¶¶¶¶¶Cardiology Hospital, Policlinico of Bari, Bari, Italy.

93 patients (69%) and absent in 42. More B-lines were found in the 3rd IS and along AA and MA lines. The B-line cumulative distribution was symmetric at rest (right/left = 1.10) and asymmetric with left lung predominance during stress (right/left = 0.67). The correlation of per-patient B-line number between 28-S and 16-S ($R^2 = 0.9478$), 8-S ($R^2 = 0.9478$) and 4-S scan ($R^2 = 0.9146$) was excellent, but only good with 1-S ($R^2 = 0.8101$). The average imaging and online analysis time were 5 s per space. In conclusion, during ESE, the comet map of lung water accumulation follows a predictable spatial pattern with *wet spots* preferentially aligned with the third IS and along the AA and MA lines. The time-saving 4-region scan is especially convenient during stress, simply dismissing dry regions and focusing on wet regions alone. (E-mail: picano@ifc.cnr.it) © 2017 World Federation for Ultrasound in Medicine & Biology.

Key Words: Exercise, Lung, Stress, Water.

INTRODUCTION

Stress echocardiography (SE) is a cost-effective imaging modality recommended by the most recent European Society of Cardiology and American College of Cardiology Foundation/American Heart Association guidelines for evaluation of coronary artery disease (CAD) and heart failure (HF) patients (Montalescot et al. 2013; Ponikowski et al. 2016; Wolk et al. 2014; Yancy et al. 2013). However, the information provided by SE extends beyond wall motion assessment and takes full advantage of the versatility of the technique to include a dynamic assessment of mitral insufficiency, pulmonary pressures, diastolic function and B-lines (Picano and Pellikka 2014). In particular, B-lines (also referred to as *ultrasound lung comets*) can be assessed by lung ultrasound (LUS) and provide a direct, positive imaging of extra-vascular lung water, a physiologic variable of well-established diagnostic and prognostic value. Only recently have B-lines entered the echocardiography (Jambrik et al. 2004; Picano et al. 2006) and later, stress echocardiography laboratory (Agricola et al. 2006; Pratali et al. 2012; Scali et al. 2017). Although experience in the field of stress-LUS is still relatively new, it has great potential to expand the diagnostic spectrum of SE (Picano and Pellikka 2016; Picano and Scali 2017). As recognized also by recent North American and European recommendations on the use of SE beyond ischemic heart disease, the demonstration of B-lines seems a feasible way for showing that exertional dyspnea is related to pulmonary congestion (Lancellotti et al. 2016). The presence of B-lines during exercise occurs in approximately 2 out of 3 patients with well-compensated heart failure with reduced ejection fraction and identifies those with more advanced functional impairment and poorer outcome in the short term. The prognostic stratification achieved with stress B-lines is more effective than that provided by resting B-lines, which are present in approximately 1 out of 3 patients (Scali et al. 2017).

At rest, LUS scanning for B-lines has been performed with a wide range of sites from extensive 72- on antero-lateral and posterior chest (Barskova et al. 2013), to a complete 28- (Coiro et al. 2015; Mallamaci

et al. 2010; Miglioranza et al. 2013), simplified 8- (Platz et al. 2016) or ultra-simplified 4- (Enghard et al. 2015) region scans. The standard stress-LUS technique has been the 28-site complete scan (Agricola et al. 2006; Scali et al. 2017), even in settings outside HF (Platz et al. 2016) when performed outdoors under extreme environmental conditions (Frassi et al. 2008; Pratali et al. 2010), but if LUS scanning has to become a part of a comprehensive SE study, imaging and analysis time is a limiting factor for acceptance. Therefore, we analyzed the feasibility and value of 5 analysis protocols for imaging B-lines during stress, comparing head-to-head the complete 28-site scan (28-S), the 16- (16-S), the 8- (8-S), 4- (4-S) and the single-site (1-S) scan in 135 consecutive patients with known or suspected HF or CAD. Patients were referred to exercise SE in 3 high-volume, quality-controlled laboratories in 3 countries (Italy, Russian Federation and Bulgaria) of the SE2020 study network, which is an ongoing large-scale, prospective, international, multicenter effectiveness study on SE in and beyond CAD (Picano et al. 2017). The primary aim of the study was to describe, on the basis of the 28-S scan, the spatial distribution of lung water in resting conditions and during stress. The secondary aim was to compare various scanning protocols to identify the most convenient one (*i.e.*, with the best trade-off between simplicity and accuracy) for adoption and large-scale validation and dissemination.

METHODS

Study population

In this prospective study, we evaluated 135 patients (45 women, 90 men; age 62 ± 12 y; left ventricular ejection fraction $41 \pm 13\%$, mean \pm SD) recruited by 3 centers of the SE2020 network (Pisa-Cisanello, Italy; St. Petersburg, Russia; and Sofia, Bulgaria). The inclusion criteria were (i) age >18 y; (ii) referral for either HF or CAD; (iii) no severe mitral regurgitation, because this condition may determine an asymmetric distribution of lung water accumulation, with predominant involvement of the right upper lobe (Schnyder et al. 1993); (iv) patient capable of exercise; (v) absence of congenital heart disease; (vi) willingness to give informed consent.

No patient was excluded because of a poor-quality LUS study at rest or during exercise.

All 135 patients underwent ESE testing as part of a clinically driven characterization. Written informed consent also allowing scientific utilization of observational data, respectful of privacy rights, was obtained from all patients before clinically driven testing. The study protocol was reviewed and approved by the institutional ethics committee as a part of the SE 2020 study.

Lung ultrasound

In the 3 centers, we used commercially available ultrasound machines (IE 33, Philips, Medical Systems, Andover, MA, USA; with a 2.5- to 3.5-MHz phased-array sector scan probe or Vivid E9, GE Healthcare, USA, manufactured in Horten, Norway, equipped or standard M5 S transducer with second harmonic technology). The depth was adjusted according to the body habitus of the patient, with thin patients requiring less depth and obese patients needing greater depth to visualize the pleural line. A B-line was defined as a discrete laser-like vertical hyperechoic reverberation artifact that arises from the pleural line extending to the bottom of the screen without fading and moving synchronously with lung sliding (Lichtenstein *et al.* 1997; Volpicelli *et al.* 2012). We analyzed the anterior and lateral hemithoraces, scanning along the parasternal (PS), mid-clavicular (MC), anterior axillary (AA) and midaxillary (MA) lines. A total of 28 chest sites were scanned and the total number of B-lines was recorded as the cumulative B-line score (Jambrik

et al. 2004). A detailed description of the scanning procedure and scanning sites is also available in a 2-min movie from our laboratory on YouTube (The incredible ULCs—ultrasound lung comets; available at http://www.youtube.com/watch?v=7y_hUFBHStM; accessed March 30, 2017). The sequence of scanning sites is shown in Figure 1. The exercise LUS study was started immediately at the end of exercise. The patient was in the left semi-supine position for transthoracic echocardiogram (TTE). LUS scanning was performed in the supine position at rest (before exercise) and soon after exercise (with the patient again resuming the supine position, Fig. 2).

The intra-observer and inter-observer variability of the B-line scores was previously assessed by 2 independent observers (who had received standardized training) in a set of 20 consecutive patients resulting in, respectively, 5% and 6% at rest and 5% and 8% at peak stress (Scali *et al.* 2017). On a set of 20 video clips selected as a part of the quality control process of the SE 2020-B-line subproject, the 3 accredited readers (Mc.S., A.Z. and I.S.) all had $\geq 95\%$ concordance with core laboratory reading on the presence and number of B-lines (judged concordant: core laboratory reader ± 1) in a set of 20 clips coming from 6 laboratories. The intra-class correlation coefficient of each of the 3 readers with core laboratory reading was >0.95 . The cardiologist-echocardiographer performing the test interpreted the B-lines. The procedure for acquisition between centers was standardized through a web-based learning module and all readers passed the quality control for both regional wall motion analysis

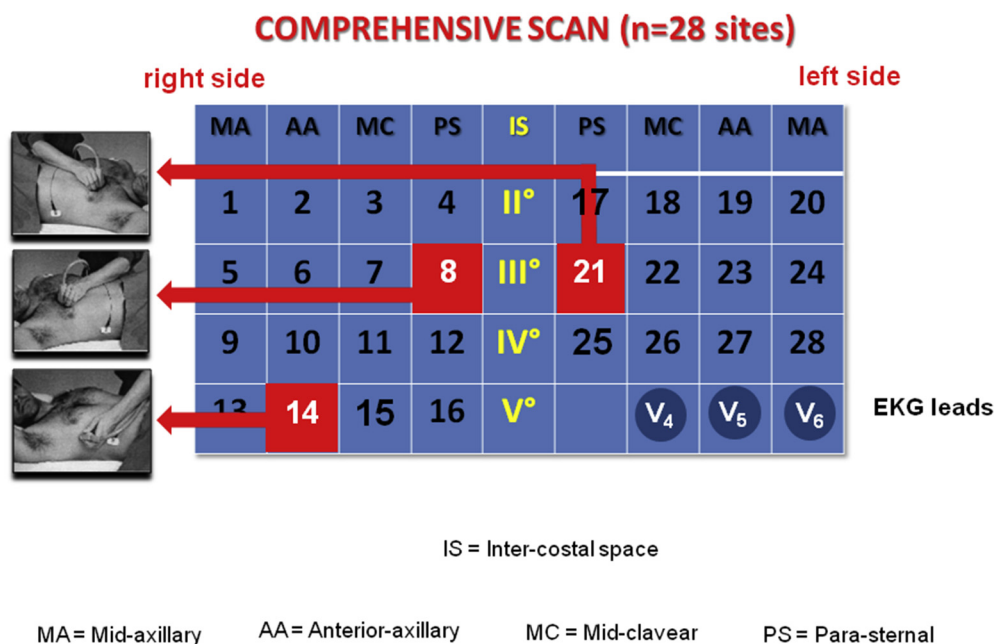


Fig. 1. The complete map of a 28-site scan of the antero-lateral chest. The V4-V5-V6 lead position is also shown for spatial reference.

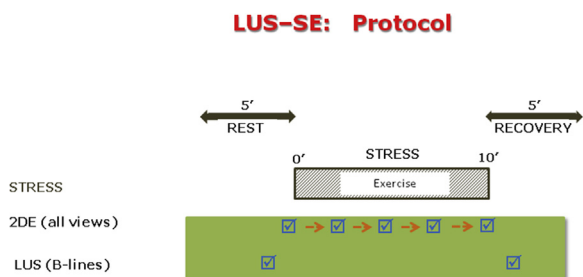


Fig. 2. Schematic diagram of standard TTE plus LUS-SE for B-lines. B-lines are acquired immediately before starting and immediately after stopping exercise. During stress, wall motion is imaged continuously. LUS = lung ultrasound; SE = stress echocardiography; TTE = transthoracic echocardiogram.

and B-lines reading upstream to starting data collection. The results for each space were entered in the data bank at the time of testing and sent to the core laboratory for analysis by an operator blinded to the study hypothesis and patient clinical data.

Terminology and numbering of spaces

The numbering and terminology adopted for scanned chest spaces was previously detailed and extensively adopted by us and other groups (Coiro et al. 2015;

Miglioranza et al. 2013; Picano et al. 2006). The spaces are numbered following the standard Latin direction of reading, from left-to-right margin, from top-to-bottom, and from the left page (right lung) to right page (left lung, the sternum being in the middle). The scanning is symmetric, with the exception of the 5th IS, present on the right lung but missing on the left lung, because the corresponding lung spaces are shadowed by the cardiac scan area.

Each space is univocally identified by a number 1–28, and more intuitively, by a straightforward alphanumeric code allowing immediate description of the horizontal and vertical alignment of the space. The first item of the code is a letter, *R* or *L*, identifying the right or left lung. The second item is an Arabic numeral, indicating the IS (2–5) and therefore the horizontal coordinate. The third item is a 2-letter code, indicating the vertical coordinate, from side margin to center: MA, AA, MC and PS.

Exercise stress echocardiography

All patients underwent semi-supine bicycle ESE according to the protocol recommended by European Association of Echocardiography (EAE) guidelines (Lancellotti et al. 2016). Graded bicycle was performed starting at an initial workload of 20 W and lasting for

SIMPLIFIED SCAN (n= 4 sites)

right side

left side

MA	AA	MC	PS	IS	PS	MC	AA	MA
5	6	7	8	III°	21	22	23	24

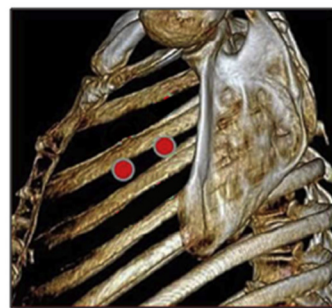
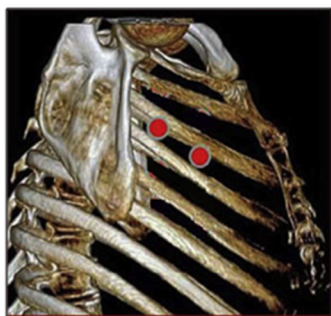

Fig. 3. The simplified scan. Sampling sites superimposed on computerized tomography chest scan (lower panel).

Table 1. Main characteristics of the patients

Age (y)	62 ± 12
Men	90 (67%)
Dilated cardiomyopathy	76 (56%)
Post-ischemic cardiomyopathy	52 (39%)
Others (CAD, valvular, HCM)	7 (5%)
Resting wall motion score index	2.09 ± 0.60
Peak wall motion score index	1.71 ± 0.64

CAD = coronary artery disease; HCM = hypertrophic cardiomyopathy.

2 min; the workload increased stepwise by 10 W at 2-min intervals. Electrocardiogram and blood pressure were continuously monitored. Criteria for interrupting the test were severe chest pain, diagnostic ST-segment shift, fatigue, excessive blood pressure increase (systolic blood pressure 240 mmHg, diastolic blood pressure 120 mmHg), limiting dyspnea, maximal predicted heart rate or significant arrhythmias. The maximum rate-pressure product (heart rate × systolic blood pressure) and exercise time (min) were also evaluated. Echocardiographic imaging was performed from parasternal long-axis view, short-axis view and 4- and 3-chamber view, using conventional 2-D echocardiography. Wall motion score index was calculated in each patient at baseline and peak stress, according to the recommendation of the American Society of Echocardiography (ASE) and the EAE from 1 (normal) to 4 (dyskinetic) in a 17-segment model of the left ventricle (Lancellotti *et al.* 2016). All physicians and nurses involved were trained in basic life support and advanced cardiac life support.

Data analysis

The data of individual spaces were entered in the 28-region scan. The analysis was later performed to calculate the number of B-lines per each space including all patients to generate a lung water map and to identify a gradient in sensitivity across various spaces, separating wet regions (with the most B-lines) from dry regions (with the least B-lines). To assess the per-patient sensitivity of each scan modality in detecting B-lines, we separately analyzed the 5 scan modes: 28-, 16-, 8-,

4- and the single 1-site scan. The 28-S scan is shown in Figure 1 and includes all spaces. The 16-S scan includes the R and L, 3 and 4 IS, with MA, AA, MC and PS lines. The 8-S scan includes the R and L, 3 IS, with MA, AA, MC and PS lines. The 4-S scan (R and L, 3, MA and AA) is shown in Figure 3. The 1-S is limited to L3 MA.

Statistical analysis

Data are expressed as mean ± standard deviation (normally distributed data such as age), median and inter-quartile (25th, 75th) range (non-normally distributed data, such as B-lines) or percent frequency (categorical data). Non-parametric Spearman correlation coefficient analysis was used to assess the relation between B-lines with various scan techniques. Assuming as the gold standard the presence or absence of B-lines at S-28 scan, for each scanning technique (S-16, S-8, S-4 and S-1) we calculated the diagnostic sensitivity, specificity, positive and negative predictive value according to standard definitions. All analyses were conducted with the Statistical Package for the Social Sciences, v. 12 (SPSS Inc., Chicago, IL, USA).

RESULTS

The demographic, resting echocardiographic and stress echocardiographic features of the study patients are reported in Table 1. Interpretable images were obtained in all spaces (feasibility = 100%).

The imaging and online analysis time (average of rest and post-stress scan for all patients) decreased sharply with the reduction in scanning sites, ranging from a median of 140 s for 28- to 5 s for a 1-site scan. At per patient analysis (Table 2), the sensitivity (>0 B-lines in any space) was 100% with 28- and decreased to 98% with 16-, 96% with 8-, 93.5% with 4- and dropped off to 77% with a 1-region scan ($p < 0.001$). The specificity was 100% with all scanning modalities (Table 2).

The per-space distribution of B-lines at rest and during stress is shown in Figure 4. The overall cumulative B-line number (considering all spaces in all patients)

Table 2. The scanning protocols: Head-to-head comparison

Type of scan	28-S	16-S	8-S	4-S	1-S
Sites (n)	28	16	8	4	1
Location	All sites	3–4 IS	3 IS	3 IS	L3 AA
Mean scan time (s)	140	80	40	20	5
Per patient sensitivity (n = 93 with B-lines)	n.a.	97.8% (n = 91)	95.7% (n = 89)	93.5% (n = 87)	77.4% (n = 72)
Per patient specificity (n = 42 without B-lines)	n.a.	100%	100%	100%	100%
Positive predictive value	n.a.	100%	100%	100%	100%
Negative predictive value	n.a.	95%	91%	87.5%	66.6%
R ² value vs 28-S scan	/	R ² = 0.9873	R ² = 0.9478	R ² = 0.9146	R ² = 0.8101

IS = intercostal space; LAA = left anterior axillary; n.a. = not applicable; S = site.

Cumulative B-lines Score

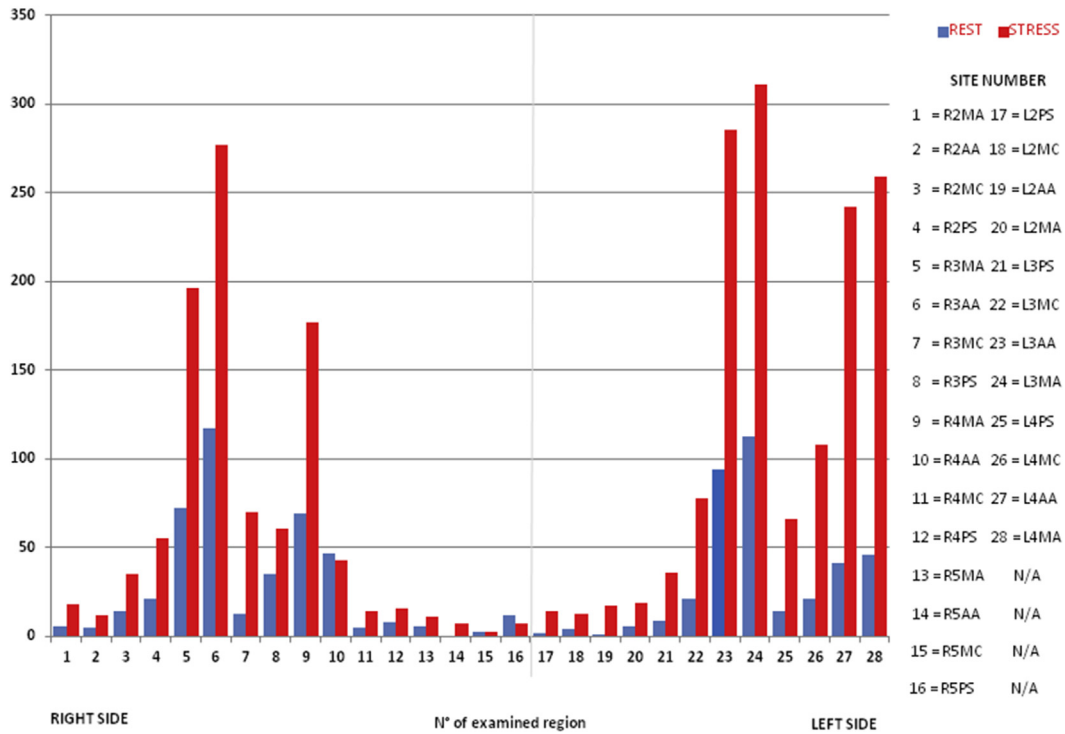


Fig. 4. Water comet distribution at rest (blue bar) and after stress (red bar). On the x-axis, the scanning sites for left (sites 1–16) and right (17–28) hemithoraces. On the y-axis, the cumulative value of B-lines with complete scan mode ($n = 28$ sites) in all patients. All B-lines from all spaces from all tests in all patients are pooled to generate the water distribution. The higher bars correspond to wet sites (with a relatively higher number of B-lines), the lower bars to dry sites (with a relatively lower number of B-lines).

increased on average 3-fold from rest to stress. The increase was about 2-fold on the right lung (cumulative value 412–974), and almost 4-fold on the left lung (372–1448). B-line cumulative distribution was asymmetric with slight right lung dominance at rest (right/left = 1.10) and pronounced left lung predominance during stress (right/left = 0.67). If the left-sided 4 spaces of the 5 IS were excluded from analysis, so that the same symmetric 12 spaces per hemithorax were included, the R/L lung ratio was 1.05 (balanced) at rest, and 0.65 (highly skewed toward the left) at peak stress.

At per-space analysis (Table 3), B-lines increased during stress, in comparison with rest, in all 28 regions except

2, where they remained unchanged (5 right mid-clavicular) or even decreased (5 right parasternal). The increase was >200 lines in absolute values (3 left mid-axillary, 4 left anterior axillary), and >500% in variation from the baseline (5 left mid-axillary, 5 left anterior axillary).

The top 3 wet sites (with higher density of B-lines) were all from the 3 IS, both at rest and during stress (Table 4).

We found a highly significant ($p < 0.0001$) correlation between the number of B-lines with 28- in comparison with the other scanning modalities, ranging from excellent (with 16-, 8- and 4-region scans) to good with the 1-region scan (Fig. 5).

Table 3. The per-space distribution of B- lines at rest and after stress (28-region scan)

	RMA	RAA	RMC	RPS	LPS	LMC	LAA	LMA
2nd IS	6– 18	5– 12	14– 35	21– 55	2– 14	4– 13	1– 17	6– 19
3rd IS	72– 196	117– 277	13– 70	35– 61	9– 36	21– 78	94– 285	113– 311
4th IS	69– 177	47– 43	5– 14	8– 16	14– 66	21– 108	41– 242	46– 259
5th IS	6– 11	0– 7	3– 3	12– 7	n.a.	n.a.	n.a.	n.a.

RMA = right mid-axillary; RAA = right anterior axillary; RMC = right mid-clavicular; RPS = right parasternal; LPS = left parasternal; LMC = left mid-clavicular; LAA = left anterior axillary; LMA = left mid-axillary; IS = intercostal space; n.a. = not applicable.

Values after stress are given in bold.

Table 4. The top-8 wet spots at rest and during stress*

Ranking	Rest	Stress
First	R3 AA (117)	L3 MA (311)
Second	L3 MA (113)	L3 AA (285)
Third	L3 AA (94)	R3 AA (277)
Fourth	R3 MA (72)	L4 MA (259)
Fifth	R4 MA (69)	L4 AA (242)
Sixth	R4 AA (47)	R3 MA (196)
Seventh	L4 MA (46)	R4 MA (177)
Eight	L4 AA (41)	L4 MC (108)

AA = anterior axillary; MA = midaxillary; MC = mid-clavicular.

* In parenthesis, the cumulative B-line score (of all patients) for each space. All the top-3 spaces belong to 3rd IS (AA and MA) both at rest and after stress.

DISCUSSION

In patients with known or suspected HF or CAD, the wet spots with higher density of B-lines are preferentially found in the 3rd IS, along the MA and AA lines, both at rest and during stress. This finding may have methodologic and pathophysiologic implications. From the viewpoint of resting TTE and SE methodology, the time-consuming 28-S scan can be conveniently replaced with the 4-S scan, with a considerable reduction of imaging and analysis time with no significant loss of information. From the pathophysiologic viewpoint, stress B-lines develop and progress potentially in a predictable manner with a left-sided predominance during semi-supine exercise, when the patient usually bends left for imaging during effort.

Selecting the right spaces

The evolution of the imaging of lung water follows in the footsteps of other parameters currently used in

stress imaging, with the initial phase of deregulation followed by progressive standardization before widespread dissemination for clinically driven use. For instance, regional wall motion analysis in the early days was characterized by the wide variability of left ventricular segments (with 5, 9, 11 and up to 20 segments). As time passed, the consensus promoted by scientific societies was to accept the 17-segment model, which made acquisition simpler, communication easier and understanding among various imaging modalities more straightforward (Cerqueira *et al.* 2002; Lang *et al.* 2015). What occurred decades ago for left ventricular segments took place again in the past decade for B-lines, the ultrasound lung comets that in a few years gained recognition and acceptance in cardiology and are now earning international guidelines and recommendations (Mebazaa *et al.* 2015). We need standardization, but we lack the critical information to rely on an evidence-based choice. The first pathophysiologic evidence is that not all spaces were created equal for lung water accumulation. In other words, the probability distribution of B-line accumulation is inconsistent across the 28 regions, but follows a predictable spatial pattern, with some regions flooded first. These regions are *wet spots*, more frequently the elective site of lung water accumulation. In particular, the L3 MA region can be used for a 1-S speed scan and represents for lung water what V5 is for 12-lead echocardiogram (ECG) in detection of myocardial ischemia during exercise-electrocardiography testing. For instance, in patients with single-vessel disease, the sensitivity of exercise-ECG is 52% using 12 leads, and 50% using only V5 lead (Fox *et al.*, 1984). L3 MA—the V5 of lung water—is vertically aligned with lead V6. The V5 of lung water can be especially useful if we think of

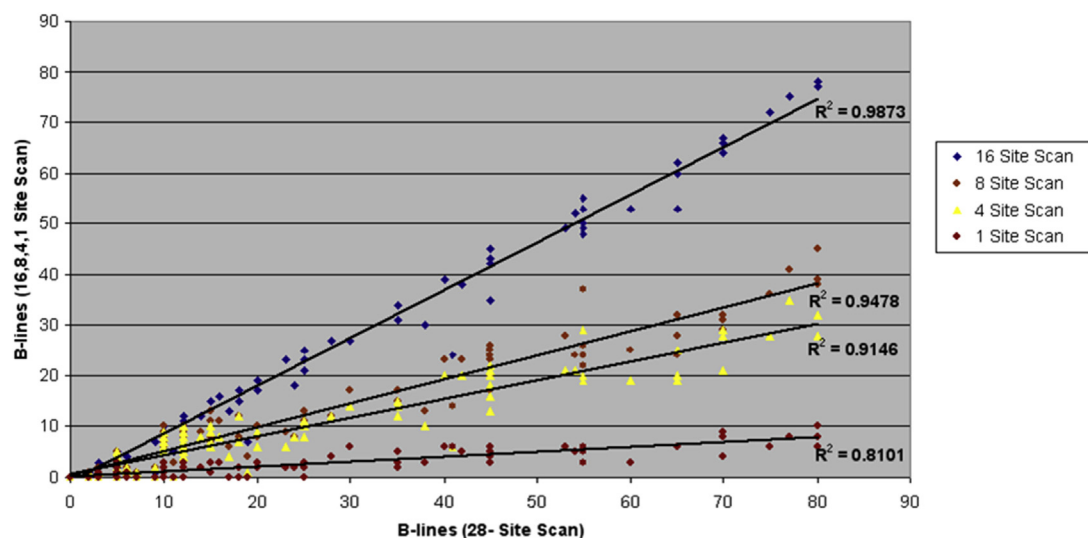


Fig. 5. On the x-axis, the number of comets for each patient with a 28-site scan. On the y-axis, the corresponding value with 16- (black), 8- (purple), 4- (yellow) and 1-site (cyan) scans.

(currently in progress) development of devices monitoring lung water on the basis of imaging or non-imaging ultrasound systems, which cannot scan the entire chest surface but must focus in a spatially limited region to track lung water accumulation, which is essential for early detection of impending heart failure decompensation. It is important to recognize that our data do not necessarily apply to other forms of exercise (upright bicycle, treadmill), where the combination of hemodynamic and gravitational stress determining lung water distribution may vary from semi-supine exercise with the patient bending leftward for imaging needs. In addition, LUS evaluates subpleural water accumulation, and therefore a direct comparison with lung water distribution observed with other methods can be difficult.

Comparison with previous studies

Our resting findings are consistent with those of Jambrik et al. (2004) and Miglioranza et al. (2013), showing that the wet spot at rest is the R3 AA space. The right lung water predominance observed at rest is switched strikingly during stress, with left lung predominance. This may have to do also with the leftward inclined position of the patient during semi-supine bicycle ESE testing, necessary to optimize ultrasound imaging but possibly superimposing the gravity stress to the usual hemodynamic stress of exercise increasing flow and pressure in the pulmonary circulation (Lewis et al. 2013). In fact, postural changes may affect the lung water distribution within a few minutes, and B-lines increase in the supine in comparison with the sitting position in HF patients (Frasure et al. 2015).

Study limitations

We studied patients with known or suspected HF or CAD who underwent semi-supine ESE. These data do not necessarily apply to other forms of pharmacologic stress or to exercise modalities different from semi-supine, such as treadmill or upright bicycle. Nevertheless, semi-supine bicycle is the most convenient and most commonly used form of stress in the SE laboratory whenever the patient is able to exercise, and is also recommended for applications beyond CAD (Lancellotti et al. 2016).

Three observers performed the B-line and SE studies in three laboratories. However, they had been trained in SE and B-lines, had established low variability in SE and B-line reading (Scali et al. 2017) and underwent an upstream quality control session dedicated to B-lines before entering the multicenter SE2020 trial, with very low variability.

The quality control was restricted to the reading of video clips, not to image acquisition, which may be variable among operators. However, the technicalities of acquisition are particularly simple for LUS, because from the

technical viewpoint LUS (for B-lines) is considered the kindergarten of echocardiography, whereas stress echo for wall motion analysis is the university—that is, more complex, time-consuming and requiring higher skills.

CONCLUSIONS

For comet watching in the SE laboratory, 28-, 16- and (to a lesser extent) 8-S scans are exhaustive but relatively time-consuming. A single-site scan is appealingly simple and fast but some significant information is lost. The best trade-off between accuracy and simplicity is the 4-S scan both at rest and after stress, when the time pressure is highest and there are so many things to see and so little time available. In this simplified form, the comet scan is user-friendly and is now undergoing dissemination and large-scale validation within the network of the SE2020 study (Picano et al. 2017).

Acknowledgments—We have no conflicts of interest to disclose. We are grateful for the expert assistance of CNR computer scientist Michele Nes for preparation of the figures.

REFERENCES

- Agricola E, Picano E, Oppizzi M, Pisani M, Meris A, Fragasso G, Margonato A. Assessment of stress-induced pulmonary interstitial edema by chest ultrasound during exercise echocardiography and its correlation with left ventricular function. *J Am Soc Echocardiogr* 2006;19:457–463.
- Barskova T, Gargani L, Guiducci S, Bellando Randone S, Conforti ML, Porta F, Pignone A, Caramella D, Picano E, Cerinic M. Lung ultrasound for the screening of interstitial lung disease in very early systemic sclerosis. *Ann Rheumat Dis* 2013;72:390–395.
- Cerqueira MD, Weissman NJ, Dilsizian V, Jacobs AK, Kaul S, Laskey WK, Pennell DJ, Rumberger JA, Ryan T, Verani MS, American Heart Association Writing Group on Myocardial Segmentation and Registration for Cardiac Imaging. Standardized myocardial segmentation and nomenclature for tomographic imaging of the heart. A statement for healthcare professionals from the Cardiac Imaging Committee of the Council on Clinical Cardiology of the American Heart Association. *Circulation* 2002;105:539–542.
- Coiro S, Rossignol P, Ambrosio G, Carluccio E, Alunni G, Murrone A, Tritto I, Zannad F, Girerd N. Prognostic value of residual pulmonary congestion at discharge assessed by lung ultrasound imaging in heart failure. *Eur J Heart Fail* 2015;17:1172–1181.
- Engelhardt P, Rademacher S, Nee J, Hasper D, Engert U, Jörres A, Kruse JM. Simplified lung ultrasound protocol shows excellent prediction of extravascular lung water in ventilated intensive care patients. *Crit Care* 2015;19:36.
- Fox RM, Hakki AH, Iskandrian A. Relationship among electrocardiographic and scintigraphic location of myocardial ischemia during exercise in one-vessel coronary disease. *Am J Cardiol* 1984;53:1529–1531.
- Frassi F, Pingitore A, Cialoni D, Picano E. Chest sonography detects lung water accumulation in healthy elite apnea divers. *J Am Soc Echocardiogr* 2008;21:1150–1155.
- Frasure SE, Matilsky DK, Siadecki SD, Platz E, Saul T, Lewiss RE. Impact of patient positioning on lung ultrasound findings in acute heart failure. *Eur Heart J Acute Cardiovasc Care* 2015;4:326–332.
- Jambrik Z, Monti S, Coppola V, Agricola E, Mottola G, Miniati M, Picano E. Usefulness of ultrasound lung comets as a nonradiologic sign of extravascular lung water. *Am J Cardiol* 2004;93:1265–1270.
- Lancellotti P, Pellikka PA, Budts W, Chaudry F, Donal E, Dulgheru R, Edvardsen T, Garbi M, Ha JW, Kane G, Kreeger J, Mertens L, Pibarot P, Picano E, Ryan T, Tsutsui J, Varga A. Recommendations for the clinical use of stress echocardiography in non-ischemic heart

- disease: Joint document of the European Association of Cardiovascular imaging and the American Society of Echocardiography. *Eur Heart J Cardiovasc Imaging* 2016;17:1191–1229.
- Lang RM, Badano LP, Mor-Avi V, Afzalalo J, Armstrong A, Ernande L, Flachskampf FA, Foster E, Goldstein SA, Kuznetsova T, Lancellotti P, Muraru D. Recommendations for cardiac chamber quantitation by echocardiography: An update from the American Society of Echocardiography and the European Association of Cardiovascular Imaging. *Eur Heart J Cardiovasc Imaging* 2015;16:233–270.
- Lewis GD, Bossone E, Naeije R, Grünig E, Saggar R, Lancellotti P. Pulmonary vascular hemodynamic response to exercise in cardiopulmonary diseases. *Circulation* 2013;128:1470–1479.
- Lichtenstein D, Mézière G, Biderman P, Gepner A, Barré O. The comet-tail artifact. An ultrasound sign of alveolar-interstitial syndrome. *Am J Respir Crit Care Med* 1997;156:1640–1646.
- Mallamaci F, Benedetto FA, Tripepi R, Rastelli S, Castellino P, Tripepi G, Picano E, Zoccali C. Detection of pulmonary congestion by chest ultrasound in dialysis patients. *JACC Cardiovasc Imaging* 2010;3:586–594.
- Mebazaa A, Yilmaz MB, Levy P, Ponikowski P, Peacock WF, Laribi S, Flachskampf FA, Foster E, Goldstein SA, Kuznetsova T, Lancellotti P, Muraru D, Picard MH, Rietzschel ER, Rudski L, Spencer KT, Tsang W, Voigt JU. Recommendations on pre-hospital and early hospital management of acute heart failure: A consensus paper from the Heart Failure Association of the European Society of Cardiology, the European Society of Emergency Medicine and the Society of Academic Emergency Medicine—Short version. *Eur Heart J* 2015;36:1958–1966.
- Miglioranza MH, Gargani L, Sant'Anna R, Rover M, Martins VM, Mantovani A, Weber C, Moraes MA, Feldman CJ, Kalil RK, Sicari R, Picano E, Luz Leiria TL. Lung ultrasound for accurate assessment of pulmonary congestion in heart failure outpatients. *JACC Cardiovasc Imaging* 2013;6:1141–1151.
- Montalescot G, Sechtem U, Achenbach S, Andreotti F, Arden C, Budaj A, Bugiardini R, Crea F, Cuisset T, Di Mario C, Ferreira JR, Gersh BJ, Gitt AK, Hulot JS, Marx N, Opie LH, Pfisterer M, Prescott E, Ruschitzka F, Sabaté M, Senior R, Taggart DP, van der Wall EE, Vrints CJ. 2013 ESC guidelines on the management of stable CAD: The Task Force on the management of stable coronary artery disease of the European Society of Cardiology. *Eur Heart J* 2013;34:2949–3003.
- Picano E, Ciampi Q, Citro R, D'Andrea A, Scali MC, Cortigiani L, Olivetto I, Mori F, Galderisi M, Costantino MF, Pratali L, Di Salvo G, Bossone E, Ferrara F, Gargani L, Rigo F, Gaibazzi N, Limongelli G, Pacileo G, Andreassi MG, Pinamonti B, Massa L, Torres MAR, Miglioranza MH, Daros CB, de Castro e Silva Pretto JL, Beleslin B, Djordjevic-Dikic A, Varga A, Palinkas A, Agoston G, Gregori D, Trambaiolo P, Severino S, Arystan A, Paterni M, Carpeggiani C, Colonna P. Stress echo 2020: The international Stress Echo study in ischemic and non-ischemic heart disease. *Cardiovasc Ultrasound* 2017;15:3.
- Picano E, Frassi F, Agricola E, Gligorova S, Gargani L, Mottola G. Ultrasound lung comets: A clinically useful sign of extravascular lung water. *J Am Soc Echocardiogr* 2006;19:356–363.
- Picano E, Pellikka PA. Stress echo applications beyond coronary artery disease. *Eur Heart J* 2014;35:1033–1040.
- Picano E, Pellikka PA. Ultrasound of extravascular lung water: A new standard for pulmonary congestion. *Eur Heart J* 2016;37:2097–2104.
- Picano E, Scali MC. Stress echo, carotid arteries and more: Its versatility for our imaging times. *JACC Cardiovasc Imaging* 2017;30243–30247. <http://dx.doi.org/10.1016/j.jcmg.2017.01.023>.
- Platz E, Lewis EF, Uno H, Peck J, Pivetta E, Merz AA, Hempel D, Wilson C, Jhund PS, Cheng S, Solomon SD. Detection and prognostic value of pulmonary congestion by lung ultrasound in ambulatory heart failure patients. *Eur Heart J* 2016;37:1244–1251.
- Ponikowski P, Voors AA, Anker SD, Bueno H, Cleland GF, Coats JS, Falk V, González-Juanatey JR, Harjola VP, Jankowska EA, Jessup M, Linde C, Nihoyannopoulos P, Parissis JT, Pieske B, Riley JP, Rosano GM, Ruilope LM, Ruschitzka F, Rutten FH, van der Meer P. 2016 ESC guidelines for the diagnosis and treatment of acute and chronic heart failure: The Task Force for the diagnosis and treatment of acute and chronic heart failure of the European Society of Cardiology. *Eur J Heart Fail* 2016;18:891–975.
- Pratali L, Cavana M, Sicari R, Picano E. Frequent subclinical high-altitude pulmonary edema detected by chest sonography as ultrasound lung comets in recreational climbers. *Crit Care Med* 2010;38:1818–1823.
- Pratali L, Rimoldi SF, Rexhaj E, Hutter D, Fajta F, Salmon CS, Villena M, Sicari R, Picano E, Allemann Y, Scherrer U, Sartori C. Exercise induces rapid interstitial lung water accumulation in patients with chronic mountain sickness. *Chest* 2012;141:953–958.
- Scali MC, Cortigiani L, Simionuc A, Gregori D, Marzilli M, Picano E. Exercise-induced B-lines identify worse functional and prognostic stage in heart failure patients with depressed left ventricular function. *Eur J Heart Fail* 2017; <http://dx.doi.org/10.1002/ejhf.776>.
- Schnyder PA, Sarraj AM, Duvoisin BE, Kapenberger L, Landry MJ. Pulmonary edema associated with mitral regurgitation: Prevalence of predominant involvement of the right upper lobe. *AJR Am J Roentgenol* 1993;161:33–36.
- Volpicelli G, Elbarbary M, Blaivas M, Lichtenstein DA, Mathis G, Kirkpatrick AW, Melniker L, Gargani L, Noble VE, Via G, Dean A, Tsung JW, Soldati G, Copetti R, Bouhemad B, Reissig A, Agricola E, Rouby JJ, Arbelot C, Liteplo A, Sargsyan A, Silva F, Hoppmann R, Breitzkreutz R, Seibel A, Neri L, Storti E, Petrovic T. International Liaison Committee on Lung Ultrasound (ILC-LUS) for International Consensus Conference on Lung Ultrasound (ICC-LUS). International evidence-based recommendations for point-of-care lung ultrasound. *Intensive Care Med* 2012;38:577–591.
- Wolk MJ, Bailey SR, Doherty JU, Douglas PS, Hendel RC, Kramer CM, Min JK, Patel MR, Rosenbaum L, Shaw LJ, Stainback RF, Allen JM, American College of Cardiology Foundation Appropriate Use Criteria Task Force. ACCF/AHA/ASE/ASNC/HFSA/HRS/SCAI/SCCT/SCMR/STS. 2013 multimodality appropriate use criteria for the detection and risk assessment of stable ischemic heart disease: A report of the American College of Cardiology Foundation Appropriate Use Criteria Task Force, American Heart Association, American Society of Echocardiography, American Society of Nuclear Cardiology, Heart Failure Society of America, Heart Rhythm Society, Society for Cardiovascular Angiography and Interventions, Society of Cardiovascular Computed Tomography, Society for Cardiovascular Magnetic Resonance, and Society of Thoracic Surgeons. *J Am Coll Cardiol* 2014;63:380–406.
- Yancy CW, Jessup M, Bozkurt B, Butler J, Casey DE Jr, Fonarow GC, Drazner MH, Filippatos G, Fonarow GC, Givertz MM, Hollenberg SM, Lindenfeld J, Masoudi FA, McBride PE, Peterson PN, Stevenson LW, Westlake C, American College of Cardiology Foundation. American Heart Association Task Force on Practice Guidelines. 2013 ACCF/AHA guideline for the management of HF: A report of the American College of Cardiology Foundation/American Heart Association Task Force on Practice Guidelines. *J Am Coll Cardiol* 2013;62:e147–e239.