

¹ Serviço de Hemodinâmica, Instituto de Cardiologia do Rio Grande do Sul/Fundação Universitária de Cardiologia, Porto Alegre (RS), Brazil.

Anterior myocardial infarction with an unusual electrocardiographic pattern

Infarto agudo do miocárdio de parede anterior com padrão eletrocardiográfico incomum

Aníbal Pereira Abelin¹ ID, Marco Tulio Zanettini¹, Carlos Antonio Mascia Gottschall¹, Alexandre Schaan de Quadros¹

DOI: 10.31160/JOTCI201927A20190002

ABSTRACT – The finding of ST segment elevation in the electrocardiogram identifies many patients with acute myocardial infarction, but presents low sensibility. Recently, some new electrocardiogram patterns have been described for the early identification of myocardial infarction. We report a case of a 53-year-old male patient who presented with an anterior myocardial infarction and an unusual electrocardiographic pattern. The electrocardiogram presented a slightly widened QRS complex, slow progression of the R wave in the anterior wall, and an ascending ST segment with tall and symmetrical positive T waves. Coronary angiography demonstrated a wraparound left anterior descending artery with medial occlusion. The original report with the abovementioned electrocardiographic pattern occurred due to occlusions in the proximal segment of the left anterior descending artery. Our patient is one of the few cases showing occlusion of the medial segment of the left anterior descending artery described after the original report of this unusual electrocardiographic pattern. This case report illustrates the problem of uncommon electrocardiogram presentations in patients with myocardial infarction.

Keywords: Percutaneous coronary intervention; Electrocardiography; Myocardial infarction

RESUMO – O achado de supradesnivelamento do segmento ST no eletrocardiograma identifica muitos pacientes com infarto agudo do miocárdio, mas com baixa sensibilidade. Recentemente, alguns novos padrões eletrocardiográficos foram descritos para identificação precoce de infarto agudo do miocárdio. Relatamos o caso de um paciente do sexo masculino, 53 anos, com infarto agudo do miocárdio de parede anterior e padrão eletrocardiográfico incomum. O eletrocardiograma apresentou complexo QRS discretamente alargado, progressão lenta da onda R na parede anterior, e segmento ST ascendente com ondas T positivas, altas e simétricas. A cineangiogramia demonstrou artéria coronária descendente anterior ultrapassando o ápice do ventrículo esquerdo e com oclusão medial. O relato original com o padrão eletrocardiográfico mencionado acima foi devido a oclusões no segmento proximal da artéria coronária descendente anterior. Nosso paciente foi um dos poucos casos de oclusão do segmento medial da artéria coronária descendente anterior descritos após o relato original desse padrão eletrocardiográfico incomum. Este relato de caso ilustra o problema de apresentações eletrocardiográficas incomuns em pacientes com infarto agudo do miocárdio.

Descritores: Intervenção coronária percutânea; Eletrocardiograma; Infarto do miocárdio

INTRODUCTION

Percutaneous coronary intervention (PCI) is the most effective method for primary reperfusion in patients with ST segment elevation myocardial infarction (STEMI).¹ Despite the introduction of care protocols based on clinical, electrocardiographic and laboratory parameters, some patients are still inappropriately discharged from the emergency department with undiagnosed acute myocardial infarction (AMI).²

An electrocardiogram (ECG) must be performed within at most 10 minutes upon admission to the emergency department, and the examination is key for making decision cases of suspected AMI. The importance of a fast screening and identification of patients with acute coronary occlusion relies on the fact that time is a powerful prognostic factor in this situation.¹ Classically, ST segment elevation is the main finding related to coronary occlusion in patients with AMI, but some new ECG patterns

Como citar este artigo:

Abelin AP, Zanettini MT, Gottschall CA, Quadros AS. Anterior myocardial infarction with an unusual electrocardiographic pattern. *J Transcat Intervent.* 2019;27:eA20190002. <https://doi.org/10.31160/JOTCI201927A20190002>

Corresponding author:

Alexandre Schaan de Quadros
Hemodynamic Service, Instituto de Cardiologia do Rio Grande do Sul/
Fundação Universitária de Cardiologia
Avenida Princesa Isabel, 370 – Santana
Zip code: 90620-000 –
Porto Alegre, RS, Brazil
E-mail: consult.asq@gmail.com

Submitted on:

Feb 23, 2019

Accepted on:

Mar 12, 2019



This content is licensed under a Creative Commons Attribution 4.0 International License.

have recently been described for the early identification of patients with acute coronary occlusion, aiming at the rapid recanalization of the artery involved in infarction.^{3,4} In this report, we present a case of anterior AMI due to acute occlusion of the mid-segment of the left anterior descending artery (LAD) with an unusual electrocardiographic expression.

CASE REPORT

A 53-year-old male patient presented to the emergency department with a severe precordial pain, dyspnea and sweating, 2 hours after onset of symptoms. Past medical

history included former smoking, hypertension and dyslipidemia. The patient was on acetylsalicylic acid (ASA) 100mg/day, metoprolol succinate 25mg/day and rosuvastatin 10mg/day. Upon physical examination, systemic blood pressure of 130/100mmHg and heart rate of 66bpm. Lung and cardiovascular examinations showed no abnormalities. A 12-lead ECG presented the following findings (Figure 1A): slightly widened QRS complex (QRS ~110ms) with nonspecific conduction disturbance in precordial leads, slow progression of the R waves in anterior wall, ascending ST segment with tall, symmetrical and positive T wave, elevation of up to 1mm of the J point, slightly elevated ST segment with upper convexity in the inferior wall (DII, DIII, and aVF) and aVR without elevation of the J point.

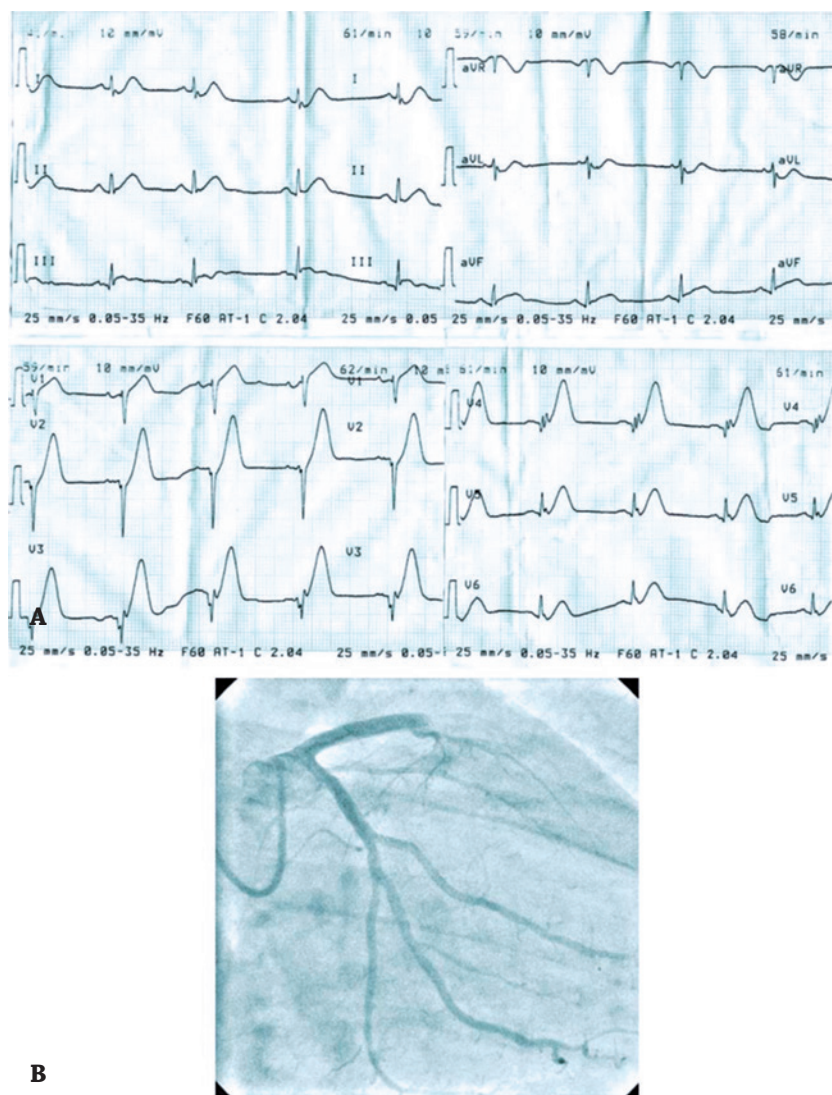


Figure 1. Pre-intervention electrocardiogram and coronary angiography. (A) A 12-lead electrocardiogram showing slightly widened QRS (QRS ~110ms) with nonspecific conduction disturbance of the precordial leads, slow progression of the R wave in the anterior wall, ascending ST segment with positive, tall and symmetrical T waves, elevation of up to 1mm of the J point, discretely elevated ST segment with upper convexity in the inferior wall (DII, DIII and aVF), and aVR without elevation at the J point. (B) Coronary angiography demonstrating a left anterior descending artery with medial occlusion (after the first septal branch) and circumflex coronary artery without significant stenosis.

Due to persistent pain and the electrocardiographic alterations described, the patient was submitted to an emergency coronary angiography (Figure 1B), which demonstrated a wraparound LAD with medial occlusion (after the first septal branch) and right and circumflex coronary arteries without significant stenosis. A primary PCI was performed (Figure 2A), with manual aspiration of thrombi and implantation of a bare metal stent, with satisfactory result (*Thrombolysis in Myocardial Infarction* – TIMI 3; Blush 3). The adjunct pharmacological therapy consisted of ASA 300mg and clopidogrel 600mg orally in the emergency department, and heparin 70IU/kg intrave-

nous and 10mg/kg of tirofiban for 3 minutes, followed by 0.15mg/kg/minute.

In-hospital clinical progression went with no adverse events. The dosages of creatine kinase-MB (CK-MB) were 111 and 51U/L after 6 and 16 hours, respectively, after the onset of symptoms. The control ECG on the third day presented findings compatible with the evolution of an AMI due to coronary occlusion (Figure 2B). Resting transthoracic echocardiography was performed on the fifth day after the AMI and showed mild systolic dysfunction of the left ventricle, with apical segment akinesia and ejection fraction of 48%. Patient was discharged on the seventh post-infarction day.

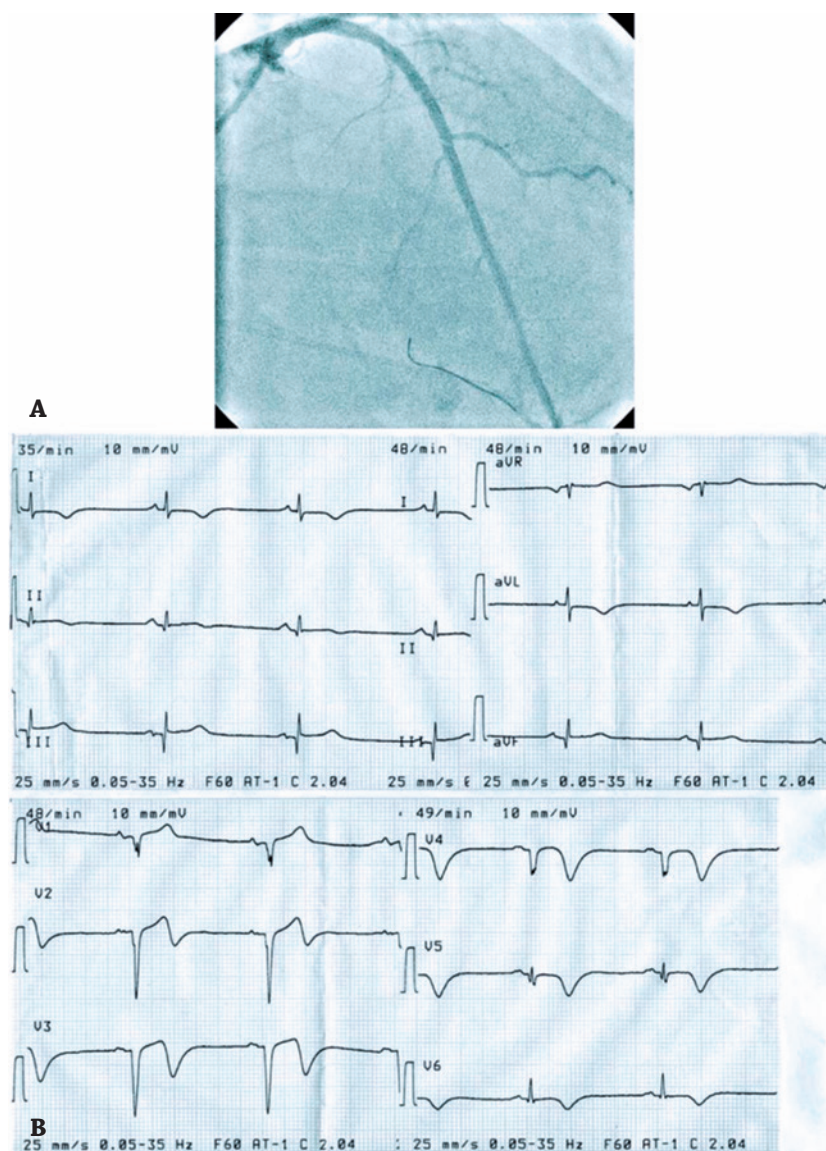


Figure 2. Post-intervention coronary angiography and electrocardiogram. (A) Primary percutaneous coronary intervention with manual thrombi aspiration and implantation of a bare metal stent, with satisfactory result (*Thrombolysis in Myocardial Infarction* 3; Blush 3). The distal tip of the guidewire is around the apex in the left anterior descending artery, in which the vessel runs on the posterior interventricular sulcus, and partially supplies blood to the left ventricle inferior wall. (B) Electrocardiogram performed on the third day post-myocardial infarction, showing reduction of the R wave voltage (DII, DIII, aVF, V5 and V6), pathologic Q wave (DIII, aVF, V1-V6) and T wave inversion (precordial leads, DI and aVL).

DISCUSSION

In the present study, we report the case of a patient with an anterior AMI, with a 2-hour delay and an unusual electrocardiographic pattern, similar to the recent report by de Winter et al.⁵ Likewise in de Winter et al. study, our patient presented a slightly widened QRS complex, slow progression of the R wave in the anterior wall, and an ascending ST segment with tall, symmetrical and positive T waves.⁵ On the other hand, there was no important depression of the J point and ST segment in the precordial leads, but this finding is not essential for diagnosing the described pattern. The presence of an occlusion in the medial segment (and not in the proximal segment) of the LAD could be the reason for this finding.

The scarce reports existent in the literature do not demonstrate a correlation of this electrocardiographic pattern with time to presentation or development of collateral circulation.⁵ In the AMI setting, these ECG findings might occur due to anatomical variation of the Purkinje fibers, or because of different pathophysiologic mechanisms in the sodium and potassium channels.⁶ All cases described by de Winter et al. in the first report of this pattern resulted from occlusions in the proximal segment of LAD.⁵ Like our patient, only a few cases showing occlusion of the medial segment of the LAD have been described after the original report of de Winter et al.⁷⁻⁹

Another uncommon observation in this case is the concomitant finding of the ST segment elevation in the inferior derivations in a patient with an isolated acute occlusion of the LAD, which presented a frequency of less than 1% in a study of 924 cases of AMI treated with primary PCI.¹⁰ These patients presented occlusion of a wraparound LAD, defined as a LAD extending around the apex to supply part of the inferior wall of the left ventricle, an angiographic characteristic observed in the case reported in this article, and in 50% of the patients described by de Winter et al.^{5,10}

The case herein reported presented the typical evolution of an AMI, with persistent precordial pain and elevation of cardiac biomarkers, but with an unusual electrocardiographic pattern. The persistence of typical chest pain despite optimized medical therapy in patients with risk factors for coronary artery disease and a non-specific ECG pattern of STEMI, is an indication to repeat the ECG for dynamic ST-segment changes, preferably with additional leads, such as V7 and V8. In these patients, emergency angiography should be performed in case of diagnostic uncertainty, to exclude the presence of coronary obstruction or to achieve coronary reperfusion as soon as possible.¹¹

CONCLUSION

We report the case of a patient with an anterior myocardial infarction caused by acute occlusion in mid-segment left anterior descending artery and an unusual electrocardiography pattern. The relevance of the present report

relies on the importance of the diagnosis of acute myocardial infarction in cases with uncommon electrocardiographic presentations, helping to reduce the inappropriate discharge of these patients in emergency department and avoiding delays in reperfusion therapy.

SOURCES OF FINANCING

None.

CONFLICTS OF INTEREST

The authors declare there are no conflicts of interest.

AUTHOR CONTRIBUTIONS

Conception and design of the study: Abelin AP, Zanettini MT, Gottschall CA, Quadros AS; data collection: Abelin AP, Zanettini MT; data interpretation: Abelin AP, Quadros AS; text writing: Abelin AP, Quadros AS; approval of the final version to be published: Abelin AP, Zanettini MT, Gottschall CA, Quadros AS.

REFERENCES

- O'Gara PT, Kushner FG, Ascheim DD, Casey DE Jr, Chung MK, de Lemos JA, Ettinger SM, Fang JC, Fesmire FM, Franklin BA, Granger CB, Krumholz HM, Linderbaum JA, Morrow DA, Newby LK, Ornato JP, Ou N, Radford MJ, Tamis-Holland JE, Tommaso CL, Tracy CM, Woo YJ, Zhao DX, Anderson JL, Jacobs AK, Halperin JL, Albert NM, Brindis RG, Creager MA, DeMets D, Guyton RA, Hochman JS, Kovacs RJ, Kushner FG, Ohman EM, Stevenson WG, Yancy CW; American College of Cardiology Foundation/American Heart Association Task Force on Practice Guidelines. 2013 ACCF/AHA guideline for the management of ST-elevation myocardial infarction: a report of the American College of Cardiology Foundation/American Heart Association Task Force on Practice Guidelines. *Circulation*. 2013;127(4):e362-e425. Erratum in: *Circulation*. 2013;128(25):e481.
- Pope JH, Aufderheide TP, Ruthazer R, Woolard RH, Feldman JA, Beshansky JR, et al. Missed diagnoses of acute cardiac ischemia in the emergency department. *N Engl J Med*. 2000;342(16):1163-70.
- Piegas LS, Timerman A, Feitosa GS, Nicolau JC, Mattos LA, Andrade MD, et al. V Diretriz da Sociedade Brasileira de Cardiologia sobre Tratamento do Infarto Agudo do Miocárdio com Supradesnível do Segmento ST. *Arq Bras Cardiol*. 2015;105(2):1-105.
- Zimetbaum PJ, Josephson ME. Use of the electrocardiogram in acute myocardial infarction. *N Engl J Med*. 2003;348(10):933-40.
- de Winter RJ, Verouden NJ, Wellens HJ, Wilde AA; Interventional Cardiology Group of the Academic Medical Center. A New ECG sign of proximal LAD occlusion. *N Engl J Med*. 2008;359(19):2071-3.
- Li RA, Leppo M, Miki T, Seino S, Marban E. Molecular basis of electrocardiographic ST-segment elevation. *Circ Res*. 2000;87(10):837-9.
- de Winter RS, Adams R, Verouden NJ, de Winter RJ. Precordial junctional ST-segment depression with tall symmetric T-waves signifying proximal LAD occlusion, case reports of STEMI equivalence. *J Electrocardiol*. 2016;49(1):76-80.

8. Goebel M, Bledsoe J, Orford JL, Mattu A, Brady WJ. A new ST-segment elevation myocardial infarction equivalent pattern? Prominent T wave and J-point depression in the precordial leads associated with ST-segment elevation in lead aVr. *Am J Emerg Med.* 2014;32(3):287.e5-8.
9. Verouden NJ, Koch KT, Peters RJ, Henriques JP, Baan J, van der Schaaf RJ, et al. Persistent precordial "hyperacute" T-waves signify proximal left anterior descending artery occlusion. *Heart.* 2009;95(20):1701-6.
10. Yip HK, Chen MC, Wu CJ, Chang HW, Yu TH, Yeh KH, et al. Acute myocardial infarction with simultaneous ST-segment elevation in the precordial and inferior leads: evaluation of anatomic lesions and clinical implications. *Chest.* 2003;123(4):1170-80.
11. Ibanez B, James S, Agewall S, Antunes MJ, Bucciarelli-Ducci C, Bueno H, Caforio ALP, Crea F, Goudevenos JA, Halvorsen S, Hindricks G, Kastrati A, Lenzen MJ, Prescott E, Roffi M, Valgimigli M, Varenhorst C, Vranckx P, Widimský P; ESC Scientific Document Group. 2017 ESC Guidelines for the management of acute myocardial infarction in patients presenting with ST-segment elevation: The Task Force for the management of acute myocardial infarction in patients presenting with ST-segment elevation of the European Society of Cardiology (ESC). *Eur Heart J.* 2018;39(2):119-77.